

More Accurate and Sensitive Diagnosis for Thyroid Tumors with Elastography –Detection and Differential Diagnosis of Thyroid Cancers–

Nobuhiro Fukunari

Department of Surgery, Showa University School of Medicine, Yokohama Northern Hospital, Kanagawa, Japan

Conventional diagnostic imaging methods could not demonstrate the objective images of tumor elasticity of the thyroid. The newly innovated technology of Elastography enable to display the tissue elasticity. As clinical evaluation of this technology for thyroid tumors, unique and characteristic images were obtained in every type of thyroid nodular disease. In case of thyroid cancer, especially, Elastography is expected to play an important role in decision making for surgical strategy.

Key Words: Elastography, Thyroid Cancer, Follicular Thyroid Cancer, Thyroid Papillary Cancer

1. Background

Palpation is an important diagnostic technique for diseases of the thyroid, as it is an organ located near the surface of the body. In particular, the hardness of a tumor is considered to be an indicator of malignancy. Recent developments in high resolution ultrasound equipment have made it easy to detect lesions that cannot be felt by palpation. However, there have been various practical difficulties associated with realizing an objective technique for visualizing the elasticity of palpable tumors. Elastography is based on the principle that when body tissues are compressed, the softer parts deform more easily than the harder parts¹⁾²⁾. In this technique, the amount of displacement at various depths is determined from the ultrasound signals reflected by tissues before and after they are compressed, and the corresponding strains are calculated from these displacements and displayed visually³⁾. This technique has already proved itself to be very useful in the detection of cancer in breast tissue. In this study, we

investigate the feasibility of applying this technique to the clinical evaluation of thyroid tumors.

Unlike with a breast, which is located between subcutaneous fat and pectoralis major muscle, with the thyroid gland, even though it is also a superficial organ, applying uniform pressure is difficult. Its convex shape and the presence of anatomical features such as the centrally located trachea, which is very different in hardness, make it difficult to conduct Elastography. Nevertheless, we are currently using Elastography for clinical examination of the thyroid with the aim of improving both the detection of thyroid cancer and differential diagnosis. In connection with this, there has been a dramatic increase in recent years in the use of FNA ultrasound for differential diagnosis of asymptomatic thyroid tumors, which are often detected with current high-resolution ultrasound. It is anticipated that the use of Elastography in conjunction with conventional ultrasound and Color-Doppler (CD)

examination will enable accurate imaging diagnosis while decreasing the number of unnecessary FNA examinations.

2. Subjects and methods

In this study we focused on thyroid tumors such as papillary cancer, follicular cancer and adenomatous goiter, which were diagnosed cytologically and were surgically treated at our institutions. Ultrasound observations were made using the EUB-8500 to obtain B-mode and tissue elasticity images with Linear probes of 6-13 MHz and display them simultaneously on the same screen. Elastography images were also compared with CT images, cytological diagnosis, surgical specimen sections, and pathological findings. Like ordinary ultrasound testing, Elastography is performed by extending the neck, placing an ultrasound probe on the neck, and pressing down slightly to apply pressure (Fig. 1). None of the patients complained of feeling any particular discomfort during the examination. When visualizing papillary lesions in the thyroid, the region of interest (ROI) was set to cover the entire thyroid including the lesion, while for lymph nodes the ROI was set to a region centered on the lymph nodes including a small amount of the surrounding connective tissue such as muscles and blood vessels.

This study investigated the clinical usefulness of Elastography for differential diagnosis of follicular tumor of the thyroid.

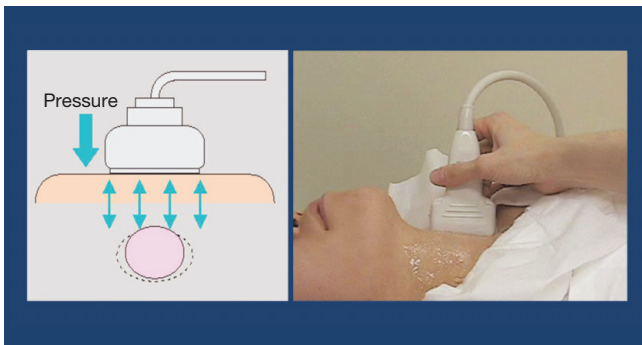


Fig. 1 : Operation of Elastography probe in thyroid

3. Results

We obtained various Elastography images, which were characteristic and unique to each of the cases in this study. As demonstrated in Fig. 2, the visualization patterns could be classified into four main patterns.

Pattern 1 : the nodule is relatively homogenous and colored light green.

Pattern 2 : the center of the nodule is colored green and its periphery is colored blue.

Pattern 3 : the nodule is colored a mixture of light green and red.

Pattern 4 : the whole tumor is hard and displayed in blue.

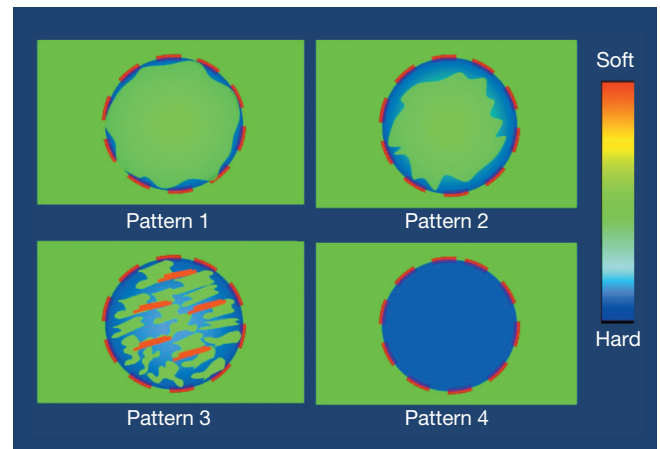
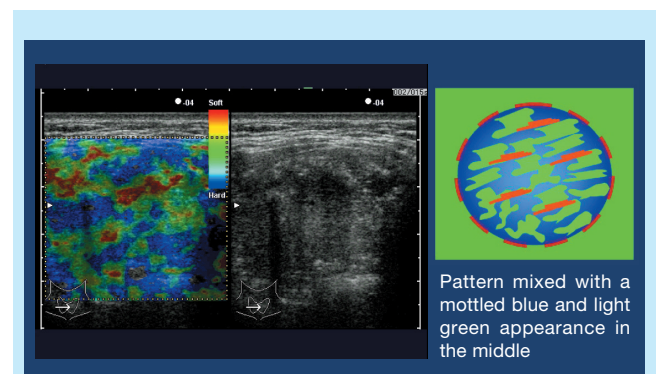
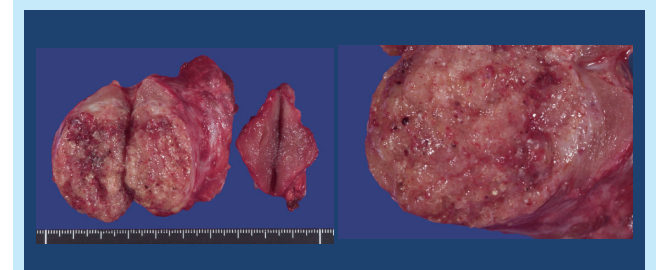


Fig. 2 : Elastography patterns in thyroid nodular disease

In cases of thyroid papillary cancer, we mainly obtained images corresponding to Pattern 3 or 4, which are thought to be characteristic findings for this condition. In the case shown in Fig. 3, B-mode images revealed hyperechoic spots in a hypoechoic region, while Elastography revealed a pattern corresponding to Pattern 3 in which hard and soft parts were mixed together (Fig. 3a). In a section taken from a surgical sample, we found a relatively soft papillary carcinoma with granular hard tissue contained in it (Fig. 3b). Fig. 4 shows another case of papillary cancer that was the solid part inside a cyst. The solid cancer part shows as



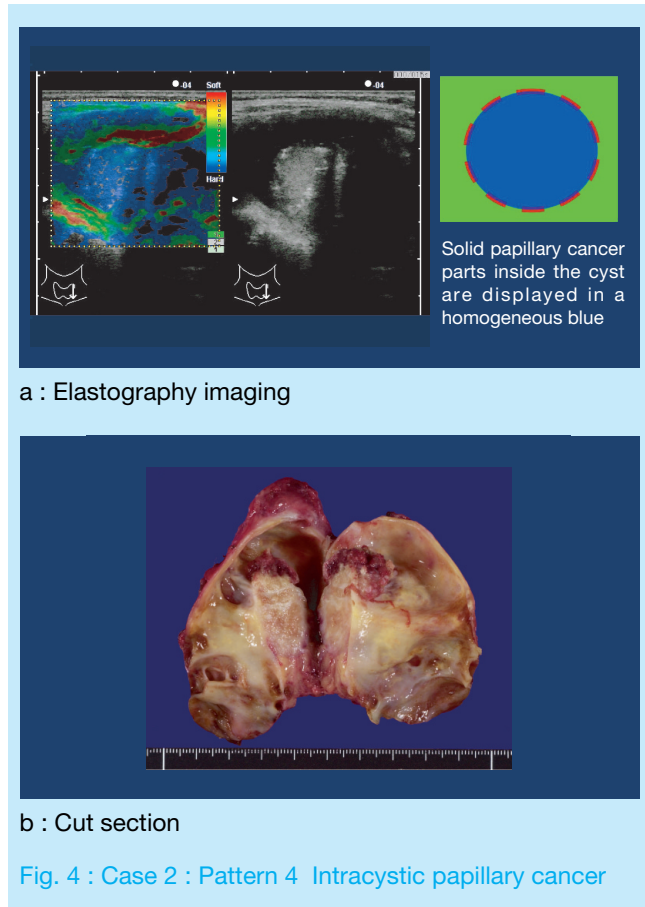
a : Elastography imaging



b : Cut section

Fig. 3 : Case 1 : Pattern 3 Thyroid papillary cancer

a hyperechoic lesion in B-mode, and was visualized as completely blue hard tissue by Elastography (Fig. 4a). The cut section revealed papillary cancer inside the cyst and showed that Elastography gives extremely similar images to the real appearance (Fig. 4b).

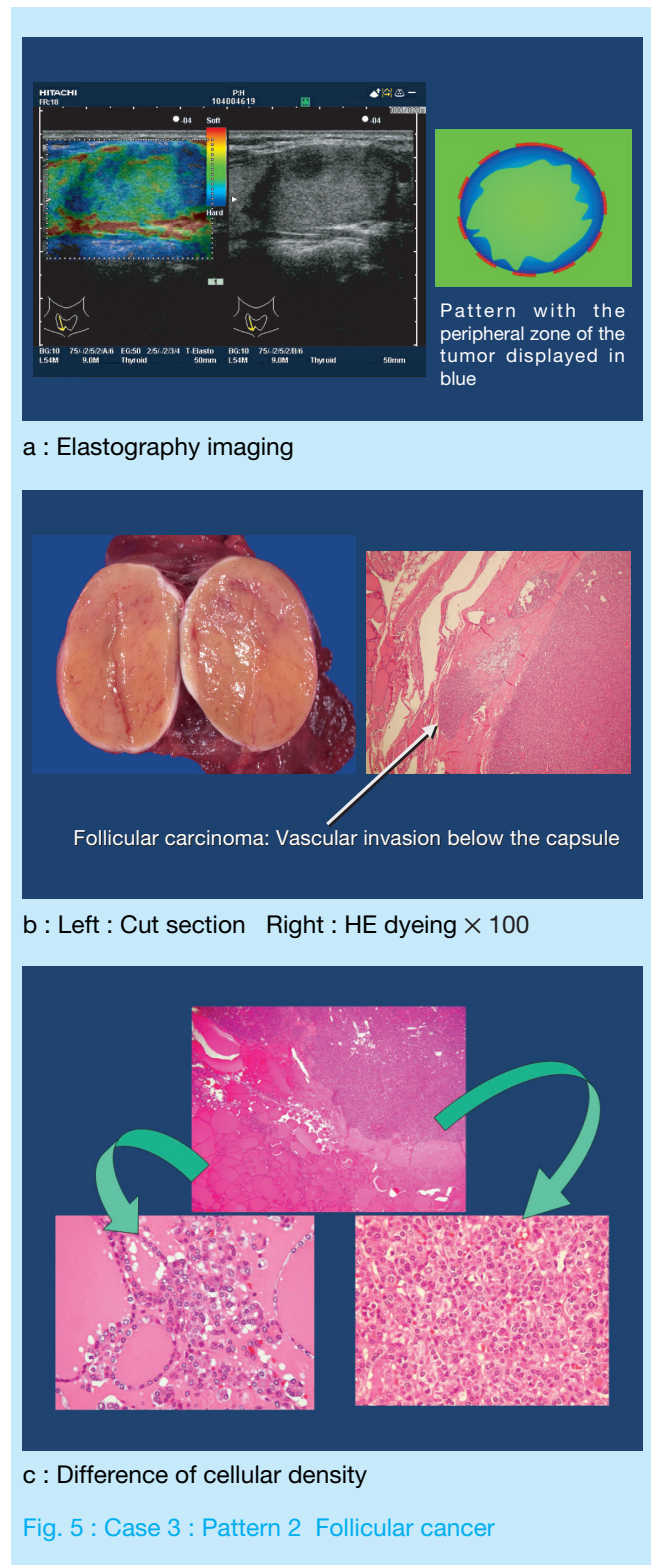


The diagnosis and management of follicular cancer of the thyroid gland remains a controversial topic. Fine needle aspiration, although very sensitive with other types of thyroid cancer, has limited accuracy with follicular lesions. The use of Color-Doppler (CD) imaging has been anticipated for the differential diagnosis between follicular adenoma and follicular carcinoma⁴⁾⁵⁾. Clinical evaluation of Elastography for the differential diagnosis of thyroid follicular lesions has been carried out in our institution. Up to the present, 88 follicular tumors have been examined by gray-scale US imaging, CD imaging and Elastography. A comparative study of these images was made and final diagnosis was determined by histological diagnosis.

All the follicular tumors were surgically and histopathologically diagnosed finally. In this series, 44 hyperplastic nodules, 28 follicular adenomas and 16 follicular cancers were found. Of the 72 benign thyroid nodules, 60 cases (83.3%) demonstrated as Pattern 1, 3 cases as Pattern 2 and 9 cases as Pattern 3. Of the 16 follicular cancers, on the other hand, 1 case demonstrated as Pattern 1, 14 cases (87.5%) as Pattern 2, and 1 case as Pattern 3, respectively.

In follicular cancers, the majority of Elastography patterns were Pattern 2. Assuming Pattern 2 to be malignant and others to be benign, 69 of 72 benign tumors and 14 of 16 follicular cancers had been accurately diagnosed, yielding a sensitivity of 87.5%, a specificity of 95.3%, and an accuracy of 94.3%.

In follicular cancer of the thyroid, the peripheral zone of the tumor tended to be hard and was displayed in blue with light green in the center as in Pattern 2 (Fig. 5a). The



blue zone at the tumor periphery in Elastography images more or less matches the hypoechoic region at the peripheral zone of the tumor shown in B-mode, and pathological examination revealed that a small irregular follicle structure had formed under the tumor capsule, which is presumed to represent hypercellularity in the peripheral zone.

Elastography can provide new useful information for the differential diagnosis of thyroid follicular tumors. Especially, Pattern 2 could demonstrate the characteristic findings of follicular cancer, which depend on the histological feature of tumor cellularity with a tighter formation at the periphery than at the center.

Finally in cases of adenomatous goiters, the whole of the tumor was displayed as light green up to the periphery of the tumor as shown in Fig. 6a, showing that the elasticity inside the tumor tends to remain relatively homogeneous. This finding differs from the pattern of Elastography obtained in cases of follicular cancer, where the periphery displayed as a blue zone. Thus, these Elastography findings show its possibility for distinguishing differences of cellularity, and also providing qualitative diagnosis of tumors.

with stable pressure. The neck contains a wide range of organs in relatively narrow compartments compared to breast tissue. Therefore, Elastography imaging for the thyroid gland will probably require longer training time to achieve images that are of value for diagnosis. Further study is needed to improve this technique particularly with respect to adjusting the pressure and the direction of the applied pressure taking into consideration anatomical structure. However, a great deal of information was obtained by combining B-mode and Elastography, and it is thought that this technique will contribute to the decision of treatment plans for thyroid disease. Furthermore, since Elastography can display the heterogeneous hardness inside a tumor and express the properties of a tumor, it should be effective for differential diagnosis. Additional clinical research should be expected in the near future.

References

- 1) Krouskop T, et al. Elastic Moduli of Breast and Prostate Tissues Under Compression. *Ultrasonic Imaging* 20, 1998: 260-274.
- 2) R. Q. Erkamp, et al. Measuring the Elastic Modulus of Small Tissue Samples. *Ultrasonic Imaging* 20, 1998: 17-28.
- 3) Hall T. Elasticity Imaging with US. *Radio Graphics* 23, 2003: 1657-1671.
- 4) Fukunari N. The role of ultrasonography and color Doppler sonography in the diagnosis of thyroid disease. *Thyroidal. Clin. Exp* 10, 1998: 97-101.
- 5) Fukunari N. Thyroid ultrasonography B-mode and color-Doppler. *Biomed Pharmacother* 10, 2002: 55s-59s.

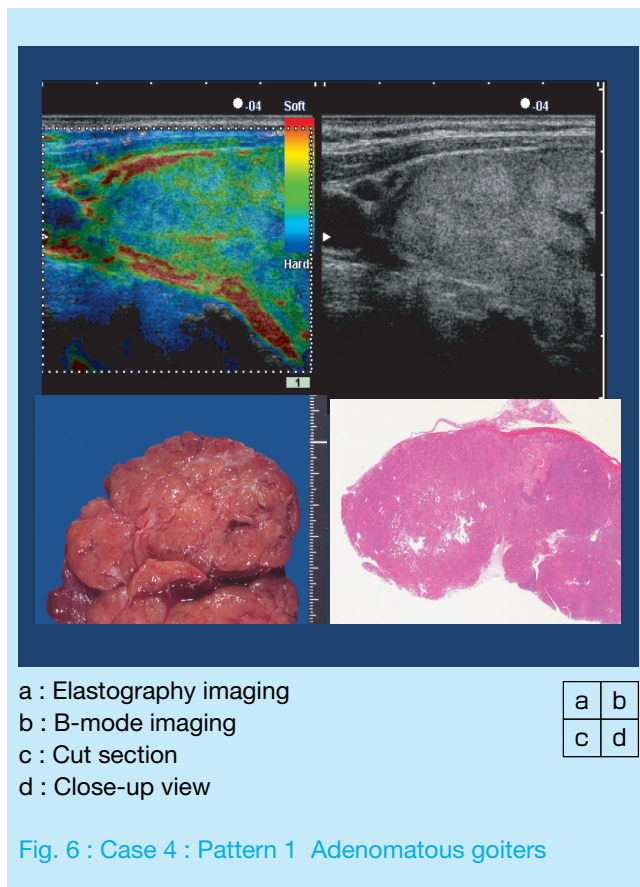


Fig. 6 : Case 4 : Pattern 1 Adenomatous goiters

4. Conclusion

In Elastography, the probe is manipulated by hand and the examined lesion is repeatedly pressed and released