

Diagnosis of Cervical Lymph Node Metastasis of Head and Neck Squamous Cell Carcinoma –Usefulness of Power Doppler Ultrasonography and Elastography–

Madoka K Furukawa¹⁾
Yoshifumi Fujita¹⁾

Akira Kubota¹⁾
Masaki Furukawa²⁾

Hideaki Hanamura¹⁾

¹⁾Department of Head and Neck Surgery, Kanagawa Cancer Center, Kanagawa, Japan

²⁾Division of Medical Informatics, Yokohama City University Medical Center, Kanagawa, Japan

Key Words: Elastography, Power doppler, Lymph nodes, Head and neck cancer, Squamous cell carcinoma, Neck masses

1. Introduction

We have routinely performed ultrasonography as the first-choice examination of neck masses since 1985. At the Department of Head and Neck Surgery, Kanagawa Cancer Center, the percentage of patients with head and neck cancer and neck masses is very high, and cervical ultrasonography is performed on more than 1,000 patients per year, including referrals from other departments. In patients with head and neck squamous cell carcinoma, in particular, the outcome often depends on the control of cervical lymph node metastasis, so the accurate diagnosis of cervical lymph node metastasis before treatment is vital for the determination of the therapeutic method. The primary topic of this report is the usefulness of power Doppler ultrasonography and Elastography for the diagnosis of lymph node metastasis of head and neck squamous cell carcinoma.

2. Subjects and Methods

Patients with head and neck cancer treated at our department were evaluated by B-mode and power Doppler ultrasonography and Elastography concerning cervical lymph node metastasis, and the results were analyzed. Whether the lymph nodes of interest were positive or negative for metastasis was determined on the basis of histopathological and cytological findings and the clinical course.

The findings on B-mode and power Doppler ultrasonographies were combined and classified into 8 patterns (Table1). The elastographic findings were classified into the following 4 patterns (Fig. 1):

Pattern 1: 80% or more of the cross-sectional area of the lymph node is red or green, i.e., soft.

Pattern 2: 50% or more and less than 80% is red or

Table 1 : Diagnostic criteria for lymph node metastasis (head and neck squamous cell carcinoma)

B-mode US	Thickness of lymph node \geq 6mm	A lymph node without the following findings	①
		Those in which the hila are observed evenly.	②
	Thickness of lymph node < 6mm	A lymph node without the following findings	③
		Nearly spherical lymph nodes in which the hila are not observed or unevenly distributed.	④
Power Doppler US	Thickness of lymph node \geq 6mm	A lymph node without the following findings	⑤
		Those in which the blood flow is distributed evenly from the hila to the entire lymph node.	⑥
	Thickness of lymph node < 6mm	A lymph node without the following findings	⑦
		Nearly spherical lymph nodes in which defects and/or disturbance are noted in the blood flow from the hila to the entire lymph node.	⑧

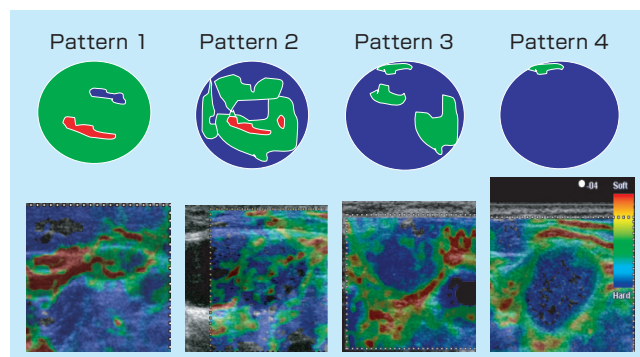


Fig. 1 : Elastography patterns of lymph nodes

Pattern 1: 80% or more of the cross-sectional area of the lymph node is red or green, i.e., soft.

Pattern 2: 50% or more and less than 80% is red or green.

Pattern 3: 50% or more and less than 80% is blue.

Pattern 4: 80% or more of the cross-sectional area of the lymph node is blue, i.e., hard.

green.

Pattern 3: 50% or more and less than 80% is blue.

Pattern 4: 80% or more of the cross-sectional area of the lymph node is blue, i.e., hard.

The ultrasonographs used was HITACHI EUB-8500 (probe: 13-6 MHz linear probe (EUP-L54M), 9-4.5 MHz linear probe (EUP-L53S)).

3. Results

Typical metastatic cervical lymph nodes with a size sufficient to be detected and diagnosed by CT or MR (thickness ≥ 10 mm) could be diagnosed relatively easily also by B-mode ultrasonography (US). Lymph nodes in which the entire interior was replaced by metastatic lesions but the capsule was nearly intact on pathological examination were imaged by B-mode US as well-circumscribed round or elliptical masses. In this mode, hyperechoic areas corresponding to the hila often disappeared, and the echo of the interior was uniform. By power Doppler US, the blood flows distributing evenly from the hila observed in normal lymph nodes were replaced by blood flows randomly entering the lymph node through the capsule (Fig. 2a and b). On the other hand, even large lymph nodes were negative for metastasis when their internal structures were intact on B-mode or power Doppler US (Fig. 2c and d).

However, stricter diagnostic criteria are necessary for small lymph nodes to avoid overlooking metastasis in head

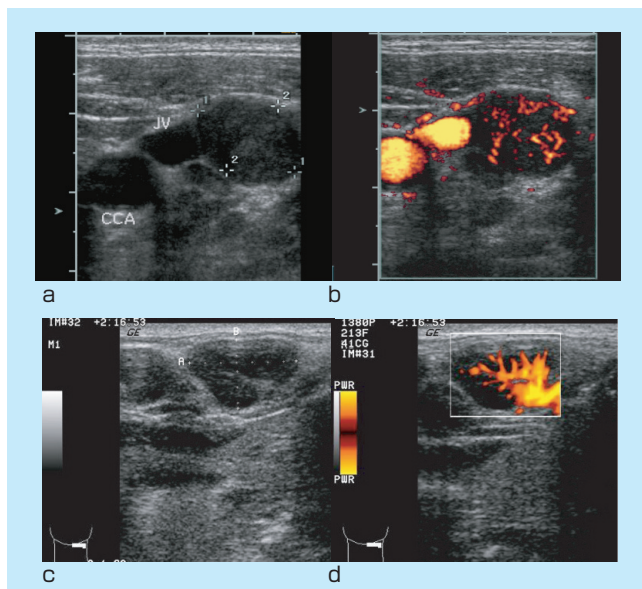


Fig. 2 : Ultrasonograms of lymph nodes positive (a, b) and negative (c, d) for metastasis

In positive lymph nodes, no hyperechoic area corresponding to the hilum is noted (a), and random blood flows are observed in their capsules and interior (b).

In negative lymph nodes, hyperechoic areas corresponding to the hila are observed (c), and blood flow distributing evenly from the hila is observed by power Doppler US (d).

and neck squamous cell carcinoma. Power Doppler US was useful for the diagnosis of small metastatic lesions located in a part of small lymph nodes (thickness: about 6 mm). Fig. 3 shows a typical example. Although the thickness of the lymph node was only 5 mm, displacement of the blood flow by a metastatic lesion was observed.

As for the diagnostic criteria based on B-mode and power Doppler US findings combined, it is considered reasonable to regard Patterns 1, 4, 5, and 8 as positive and the other patterns as negative for metastasis.

Concerning Elastography, the findings in patients recently examined at our department were classified. Of the 34 metastasis-positive lymph nodes, 32 showed Pattern 3 or 4 (Fig. 4). However, all 11 negative lymph nodes were

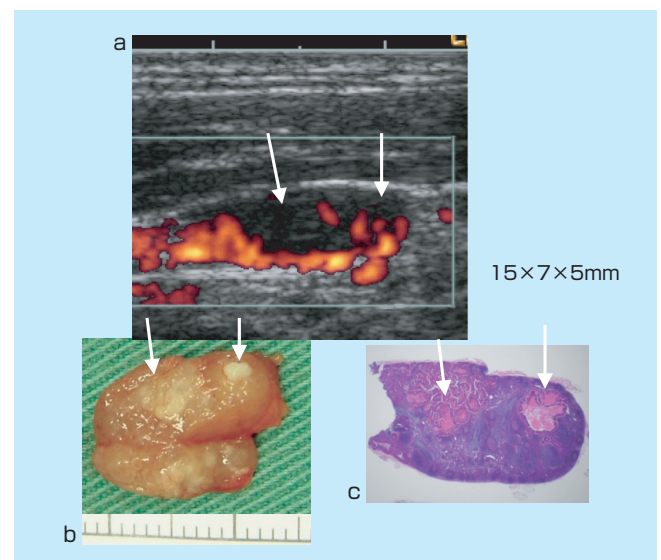


Fig. 3 : Small metastatic lesions detected by ultrasonography In this lymph node, which was $15 \times 7 \times 5$ mm, defects in blood flow were noted by power Doppler US (arrows) (a). Small metastatic lesions were found at the sites of blood flow defects (b, c).

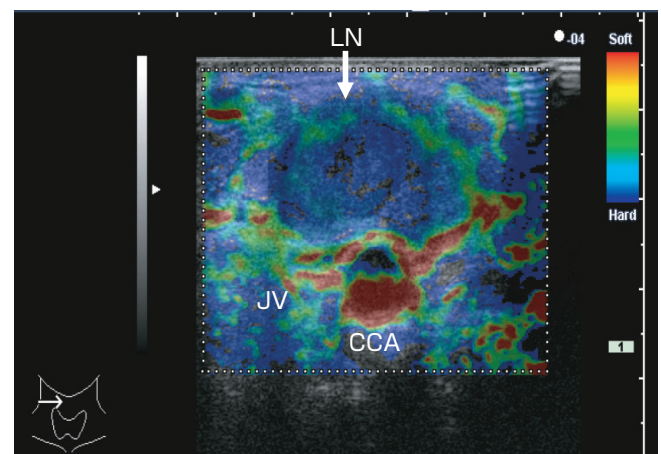


Fig. 4 : Elastography of metastasis-positive lymph nodes Lymph nodes with metastasis are shown as masses that are entirely blue or blue mixed with small areas of green (LN: Lymph node. CCA: Common carotid artery. JV: Jugular vein).

classified as Pattern 1 or 2 (Fig. 5).

Next, Elastography before and after chemotherapy are presented to evaluate the effectiveness of the therapy. Case 1 was a patient with cervical lymph node metastases of hypopharyngeal cancer. Elastographic findings before and after simultaneous chemoradiotherapy were compared. Before treatment, the lymph node was shown as a generally blue area, indicating a hard mass (Pattern 4) (Fig. 6a). After treatment, no marked change was noted in the size of the lymph node on B-mode US, but Elastography showed the lymph node as a soft mass, in which 50% or more of the cross-sectional area was green or red (Pattern 2) (Fig. 6b). B-mode US performed after 6 months morphologically indicated the disappearance of lymph node metastasis. Two years after treatment, this patient has been following an uneventful course without recurrence.

Case 2 was a patient with cervical lymph node metastasis of oral cancer. A metastatic lymph node after preoperative chemotherapy was examined by Elastography. The

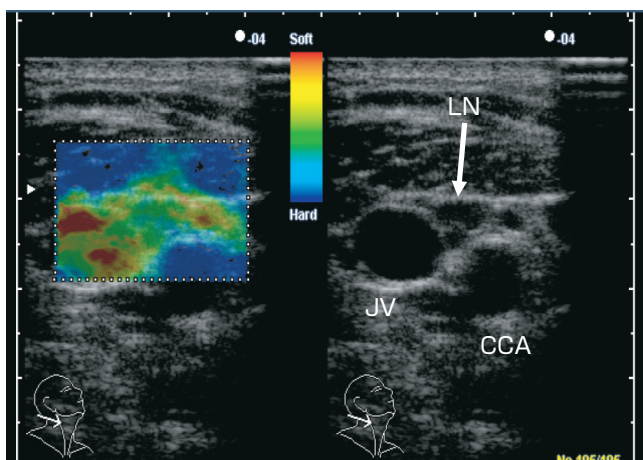


Fig. 5 : Elastography of metastasis-negative lymph nodes
Lymph nodes negative for metastasis are shown as entirely green areas.
(LN: Lymph node. CCA: Common carotid artery. JV: Jugular vein).

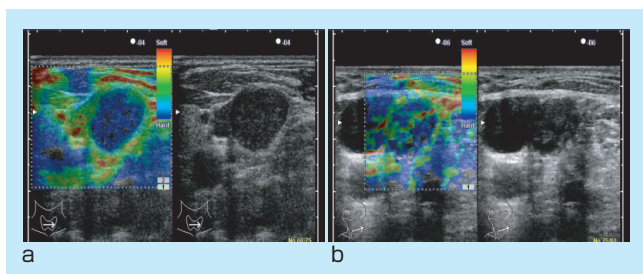


Fig. 6 :
Case 1: Elastography of a metastatic cervical lymph node in a 64-year-old male with hypopharyngeal cancer
a. (Before treatment) The metastatic lymph node was shown as an entirely blue, i.e., hard, mass (Pattern 4).
b. (After chemoradiotherapy) The metastatic lymph node was shown as an area that is basically blue mixed with green and red parts (Pattern 2).

metastatic lymph node, palpated in the left upper neck before treatment, became hardly palpable following chemotherapy. The lymph node after chemotherapy was represented as blue near the margin, but green, indicating soft tissue, near the center (Pattern 3) (Fig.7). Examination of the resected lymph node revealed cystic changes of the interior with fluid retention. Histopathologically, cancer cells were noted in the cyst wall.

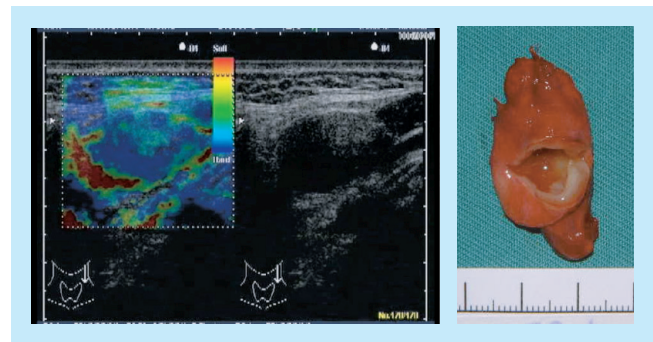


Fig. 7 :
Case 2: Elastography of a metastatic cervical lymph node in a 71-year-old female with oral cancer (after chemotherapy)
In the metastatic lymph node following treatment, green parts appeared in a basically blue area (Pattern 3), and cystic changes were observed in the interior of the resected lymph node.

4. Discussion

In patients with head and neck cancer, CT and MRI are performed uniformly for the diagnosis of the primary focus at many facilities, and these techniques are also used for the diagnosis of cervical lymph node metastasis. However, diagnostic criteria for lymph node metastasis are not necessarily appropriate. Lymph nodes judged to be negative or those that are even undetectable by CT or MRI are often positive for metastasis, and ultrasonography is effective in the examination of such patients. We initially suspected lymph nodes with a thickness of 6 mm or greater in B-mode images to have metastasis, because a small metastasis in a lymph node first causes changes in its vertical dimension relative to the body axis, i.e., thickness, and the possibility of metastasis is high when the thickness increases to 6 mm or greater. However, the judgment of whether there is metastasis, which should be properly made at the microscopic level, according to the size of the lymph node alone is naturally impossible. While lymph nodes 6 mm or greater in thickness are often negative for metastasis, those less than 6 mm in thickness are often positive, and false negatives or false positives cannot be completely eliminated whatever level the criterion may be set at. On the other hand, as small metastatic lesions in

lymph nodes can be detected by close examination of internal echoes using a high-resolution ultrasonography¹⁾ or combining the findings with those by power Doppler ultrasonography concerning the blood flow of the lymph nodes²⁾, we classified lymph nodes according to the state of internal echoes as well as the size. Since changes in metastatic lymph nodes differ according to the histopathological type, we applied these criteria to squamous cell carcinoma only.

Elastography, which we used to obtain information concerning hardness, is a technique of repeatedly applying and relieving pressure to the tumoral lesion from the body surface using a probe, calculating the distortion caused by this, which differs according to the hardness of the tissue, and imaging variations in hardness in different colors. This technique, by which the hardness of the mass can be objectively represented as static as well as dynamic color images, is presently employed effectively for the differential diagnosis of mammary gland tumors³⁾ and is also applied tentatively to the diagnosis of thyroid and parathyroid tumors. Elastography is also expected to be useful for the examination of cervical lymph nodes since they are close to the body surface and can be compressed without interference by bone or cartilage, similarly to mammary glands and the thyroid gland.

Before the development of various imaging techniques to today's level, cervical masses were diagnosed exclusively by palpation. There are also many lymph nodes of a considerable size in the neck in healthy people. However, in a strict sense, normal lymph nodes are rarely detected by palpation. Therefore, if lymph nodes present some morbid findings (including reactive ones) and are palpable, hardness evaluated by palpation is important information. Elastography made it possible to visualize this hardness. Tissues showing low-level distortion are indicated as blue, with those showing marked distortion as red. Metastasis of cancer to cervical lymph nodes often makes them harder, and they are shown primarily as a blue area, indicating hard tissue (Patterns 3 and 4). In contrast, lymph nodes without metastasis are revealed as soft masses represented primarily as green areas (Patterns 1 and 2). Since lymph nodes are rarely shown as primarily red areas, their Elastography range between green and blue. By B-mode ultrasonography, also, masses are compressed with the probe, their movements relative to those of muscles, blood vessels, and other surrounding tissues are evaluated in real-time, and their hardness is estimated to judge whether there is metastasis. Compared with this procedure, the visual grading of hardness by Elastography requires no particular skill, is highly objective, and is very useful.

Metastatic lesions present in part of a lymph node, such as those shown in Fig. 3, are also expected to be shown by

Elastography to be harder than surrounding normal lymphatic tissues, and improvements in the diagnostic accuracy are expected from the combination of these findings with those by power Doppler US.

After radiotherapy or chemoradiotherapy of head and neck cancer, the precise evaluation of therapeutic effects on cervical lymph node metastasis is required for the judgment of the necessity of cervical lymph node dissection. In many patients receiving chemotherapy or radiotherapy for cervical lymph node metastasis, metastatic lymph nodes become impalpable with the progression of treatment, but their size shows no marked change when evaluated by imaging techniques, particularly ultrasonography. Since one of the reasons for such a phenomenon is the softening of lymph nodes with no marked change in their size, we compared Elastography before and after treatment. Elastography after treatment reflected pathologic changes in lymph node tissues and were very useful in Patients 1 and 2. Therapeutic effects on metastatic lymph nodes have been evaluated according to alterations in the blood flow in the lymph nodes evaluated by B-mode and power Doppler ultrasonographies, but Elastography, which visually presents the hardness of lymph nodes, was found to allow clinical and objective evaluation of quantitative changes in lymph nodes from the same viewpoint as palpation.

5. Closing remarks

Ultrasonography plays a very important role in the examination of cervical lymph nodes. The areas of application of ultrasonography, which is non-invasive and inexpensive, will continue to widen. Also, various new techniques associated with ultrasonography including Elastography are being developed, and the precision of the diagnosis of cervical lymph node lesions is expected to be improved further.

References

- 1) Vassallo P, et al. Differentiation of benign from malignant superficial lymphadenopathy: the role of high-resolution US. *Radiology*, 1992; 183:215-220.
- 2) Na DG, et al. Differential Diagnosis of Cervical lymphadenopathy: Usefulness of color Doppler sonography. *AJR*, 1997; 168:1311-1316.
- 3) Itoh A, et al. Breast disease: Clinical Application of US Elastography for Diagnosis. *Radiology*, 2006; 239:341-350.