

The Musculoskeletal Elastography

Giuseppe Monetti¹⁾

Paolo Minafra²⁾

¹⁾*Institute of Sport Medicine, University of Bologna, Italy*

²⁾*Chair of Sport Medicine, University of Palermo, Italy*

Elastography study is a valid support in the clinical evaluation of musculoskeletal tissues. The elastographic investigation in the musculoskeletal field, allows good evaluations, in a functional point of view, because it permits to measure the stiffness of the tissues. Muscles and tendons bear their greater elasticity in the moment of contraction and it is for this reason that the investigation has to be effected foreseeing this, muscles and tendons movement.

Ultrasound method is universally acknowledged as a first standard examination in distraction muscular traumas, thus allowing immediately the appraisal of all the areas involved, especially thanks to the dynamic evaluation of the muscular components.

The possibility of assessing also the elasticity degree of fibres, once scar-formation has been completed, is a further complementation of the ultrasound study, considering how difficult it is often to diagnose, in recovery, the real healing of impaired tissues.

Key Words: Elastography, Ultrasound, Musculoskeletal Pathology, Functional Study

1. Introduction

Thirty athletes practicing professional sports were evaluated in the steps after post-trauma muscular distraction of the inferior limb, using a state-of-the-art ultrasound equipment provided with Elastography method. Such method is known to provide information about the quality of soft tissues, assessing minor or major elasticity, which is significantly useful in the clinical and therapeutic follow-up of muscular lesions. The thirty athletes aged between 18 and 42, were assessed 4 weeks after trauma.

In a preliminary phase it has been estimated the answer of the musculo-tendinous tissues in physiological conditions, in clino and ortosthesis¹⁾²⁾.

2. Main subject

The elastographic examination confirms that during the contraction, the muscles underline a colorimetric staircase that proves accented elasticity. The same concept can be

applied to the tendons study, with different answers, depending on if the examination is performed in clinostasis or in orthostasis.

In fact, we showed that in upright position the tendinous insertions, for a higher stabilization, develop a greater resistance, above all physiological, that perfectly corresponds to the elastographic map. Fig. 1 shows a patellar tendon in weight bearing in which is possible to find a great representation of green-blue colour, strictly related to the functional stabilization especially in the distal insertion, while the proximal portion is normally more red-yellow coloured.

The evaluation of functional anatomy is another important application of Elastography because it can help the study of muscles and tendons even in small traumas, characterized by the non-appearance of any evident lesion with standard B-mode examination.

With pathologies, the elastographic investigation results excellent, especially in the monitoring of traumas, both tendinous and muscular, whereas the scan fibrosis determines a clean diminution of elasticity of the tissues.

The intervention of this methodology allows therefore a functional evaluation and it is able to monitor alterations, in order to establish with higher accuracy the opportune moment when the injured athlete can resume the competitive activity.

In all patients with muscular traumas, the elastographic examination showed irregular areas and assessed several degrees of altered intrinsic elasticity in site of the lesions and especially in peri-lesion areas, that in mere B-mode examination seem unaffected by post-traumatic problems, while in ultrasound they result extremely important to plan the functional recovery of the muscular tissue impaired³⁾.

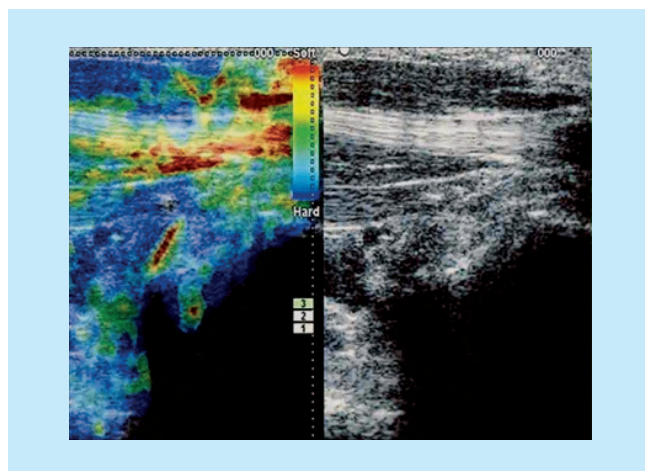


Fig. 1 : Fisiological dynamic examination in upright position patellar tendon

This is the case showed in the Fig. 2, where it's evident that the fibrosis determines a large peri-lesional area with prevalent blue colour representation where, depending on the time of the examination, it's possible to find also some red areas; this kind of findings confirm that fibrosis habitually has a period of reorganization especially after a physiotherapeutic treatment, that always need a certain feed-back to understand the real efficacy of any treatment.

Fig. 3 give you an idea about the utility of Elastography in the follow-up of a high-grade muscular partial tear, in which the hypo-echoic area, normally related to a fluid haematoma, in its place is to defined as an hard tissue; the relevant presence of the blue colour disclose the existence of the scar forming in a really early phase.

In the evaluation of partial tears, the Elastography it's important not only to appreciate the lesions, but also to have more relevant information about the entire muscular structure involved in traumas.

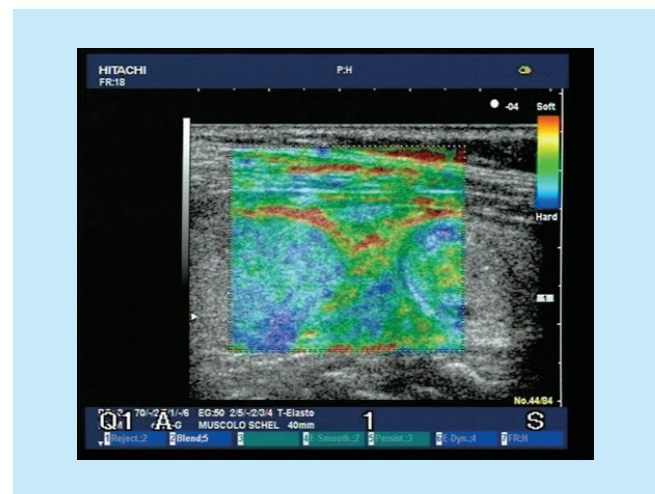


Fig. 2 : Post trauma fibrosis

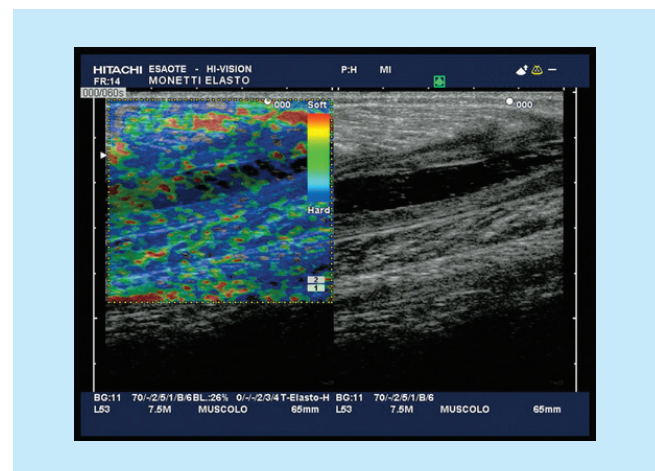


Fig. 3 : Non fluid hypoechoic post traumatic area

In the image Fig. 4, is shown the comparative study between standard examination and Elastography of a partial tears in the rectus femori; in this case is evident how the small lesion determines a functional impairment of all the quadriceps, as it appears by muscular colour indication with green-blue colour, normally related to less elasticity.

Another sector of the muscle-skeletal pathology where Elastography can be very useful is the study of the benign and malignant tumors, because they always determine an answer of greater or smaller elasticity in consideration of their content.

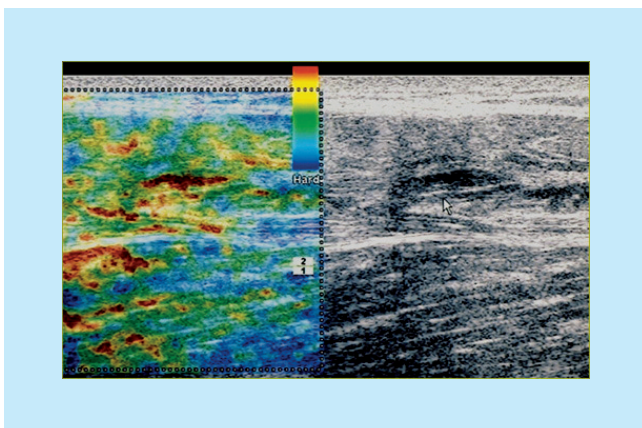


Fig. 4 : Partial tear of rectus femori axialscan

3. Conclusions

Elastography is a valid support in the study of muscle-skeletal pathology, because not only it gives an accurate appraisal of the entity of the lesion, but also shows the state of the peri-lesion area, indispensable in the clinical and therapeutic follow-up of muscular lesions, allowing thus a more correct evaluation of the functional recovery in relation to the actual condition of muscular fibres involved in the repair process.

Moreover the functional study in different degrees of motion, related to the common sport activity, turns out to be determinant in the healthy subject, estimating from time to time the structures of reference for every practiced discipline, in the evaluation of acute/sub-acute traumatic pathologies or degenerative post-trauma outcomes.

Therefore, we consider that this methodology can always provide us, more and more, with greater information in order to obtain a more complete diagnosis for the future.

References

- 1) G. Monetti, et al. Functional aspects of muscles whit Elastography. National Congress of Musculoskeletal Radiology. 19-21 May 2005. Rimini, Italy.
- 2) G. Monetti et al. Functional examination in weight bearing in musculoskeletal pathology: ultrasound vs RM. – National Congress of Musculoskeletal Radiology. 17-19 May 2007. Pesaro, Italy.
- 3) P. Minafra, et al. Elastography in the evaluation of the post-traumatic muscular pathology – 8th Congress of the International Society for Musculoskeletal Ultrasound. 20-23 September 2006. Warsaw, Poland.