

Real-time Tissue Elasticity Imaging (Elastography) for Prostate Cancer Detection

Masakazu Tsutsumi¹⁾
Takeshi Matsumura³⁾

Tomoaki Miyagawa²⁾
Satoru Ishikawa¹⁾

¹⁾Department of Urology, Hitachi General Hospital, Ibaraki, Japan

²⁾Department of Urology, Kitaibaraki Municipal General Hospital, Ibaraki, Japan

³⁾Design Department, Ultrasound System Division, Hitachi Medical Corporation, Chiba, Japan

Key Words: Real-time Tissue Elastography, Prostate Cancer, Transrectal Ultrasonography

1. Introduction

Stiffness of tissue is important information for cancer diagnosis, and it is also very commonly used for prostate cancer diagnosis. Digital rectal examination (DRE) is the easiest method to detect prostate cancer, but it has limited reproducibility, and lacks objectiveness. The positive predictive value of DRE alone has been shown to be as low as 30%. The second easiest imaging technique used for tumor location is transrectal ultrasonography (TRUS). One of the drawbacks of this technique is that location of tumors is often misjudged. In TRUS, cancer lesions are initially detected as low echoic lesions, but it is now recognized that cancer lesions may appear as hypo-, hyper-, or iso-echoic areas. For this reason, most urologists recognize that TRUS tends to provide guidance for biopsy, but is not used as a screening tool. Combination with DRE does not improve the detection of prostate cancer. Magnetic resonance imaging (MRI) is currently a promising tool to detect prostate cancer, and was reported to significantly increase the accuracy of prostate cancer diagnosis. Various studies have shown that MRI has sensitivity ranging from 51~95%, and specificity from 67~100%. However, the disadvantage of MRI is its lack of real-time feedback for prostate biopsy.

The ultrasound real-time elasticity imaging system (Elastography) is a new technology that visualizes differences in tissue strain by free-hand compression. This technology is popular for use in examining breast lesions. Because breast cancer is harder than the adjacent normal breast tissue, palpation and also Elastography are used in the clinical assessment of breast abnormalities. Similar to

breast lesions, prostate cancers generally are hard, and therefore Elastography is applicable for prostate cancer detection. Additionally, Elastography is substantially more useful than MRI because simultaneous TRUS biopsy can be performed viewing both B-mode and Elastography images. However, Elastography for the prostate has many disadvantages compared with that for breast lesions. One is that, whereas the compression site on a breast is visible, making the procedure easy, prostate examination requires the use of a transrectal probe and so the compression site is not visible and range of motion is small, making the procedure difficult (Fig. 1). Another disadvantage is that compared to a breast, the dynamic range of hardness between normal and cancerous tissue in the prostate is narrow¹⁾ (Fig. 2).

Because of these handicaps, there have only been a few reports of Elastography regarding prostate disease so far including our own²⁻⁵⁾. Konig et al. reported the use of real-

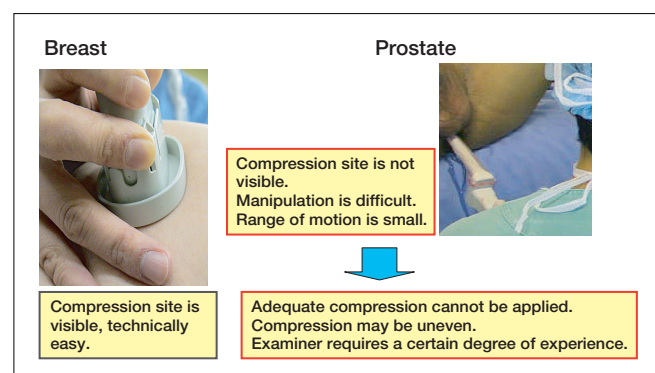


Fig. 1 : One of the disadvantages of Elastography for prostate compared with breast; Difference of manipulation

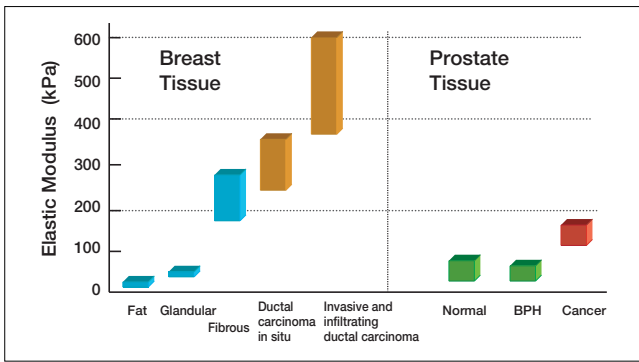


Fig. 2 : Another of the disadvantages of Elastography for prostate compared with breast; Difference of distribution of stiffness between prostate and breast

time Elastography for biopsy of the prostate, and this technique was determined to be useful for detecting prostate cancer: it achieves sensitivity rates up to 84.1% in comparison to only 64.2% by conventional diagnostic modalities²⁾. Miyanaga et al. also reported that Elastography detected 93% of untreated prostate cancer, which was significantly higher than digital rectal examination (59%) or digital rectal ultrasonography (55%)³⁾. Since 2004, we have performed transrectal ultrasonic (TRUS) biopsy of the prostate concomitantly with Elastography. Our manuscript was the first report to describe the elastographic characteristics compared with the clinicopathological findings based on diagnostic criteria⁴⁾.

In this report, we describe the result of clinicopathological evaluation of real-time tissue elasticity imaging (Elastography) for prostate cancer detection.

2. Exclusion criteria and a diagnostic classification system of Elastography for the prostate

In order to increase the quality of Elastography, positive feedback by evaluating the feasibility of Elastography comparing elastographic images with pathological sections is mandatory. Before the evaluation, we have to maintain the objective reading of Elastography. For these reasons, we first of all made exclusion criteria and a diagnostic classification system for elastographic analysis for prostate cancer.

(1) Exclusion criteria

For this elastographic analysis, we made four exclusion criteria: two depend on the examiner's skill, and the other two are derived from characteristics of the prostate.

1) Factors dependent on the examiner's skill (Fig. 3)

Images indicating inadequate compression of the tissue should be excluded.

- a. Heterologously changing blue region during compression ①
- b. The surface of the prostate was not revealed as a red color. ②

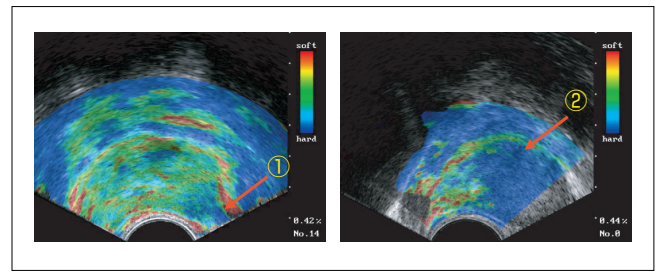


Fig. 3 : Exclusion criteria of Elastography due to factors dependent on examiner's skill

2) Factors derived from characteristics of the prostate (Fig. 4)

The area around non-echoic regions should be excluded.

- a. Blue-colored findings around calcification ①
- b. Anterior fibromuscular stroma region (AFS) ②

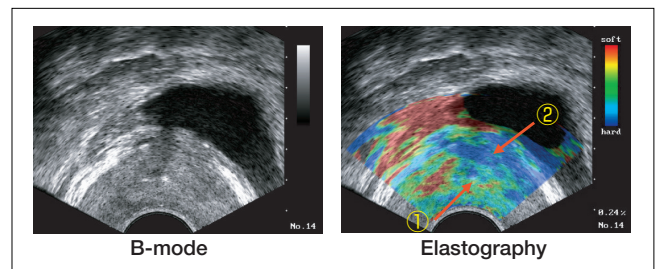


Fig. 4 : Exclusion criteria of Elastography due to the factors derived from characteristics of the prostate

(2) Diagnostic classification system

We additionally made a classification system for each elastographic moving images (EMI), and each case.

1) Each EMI (Fig. 5)

Positive elastographic locus was defined as E(+), negative as E(-). In the pathological section, the presence of a cancer lesion was defined as p(+), and the absence of a cancer lesion as p(-). In this system, E(+)/p(+) indicates that Elastography exactly revealed cancer lesions, while E(+)/p(-) means false positive and E(-)/p(+) means false negative findings.

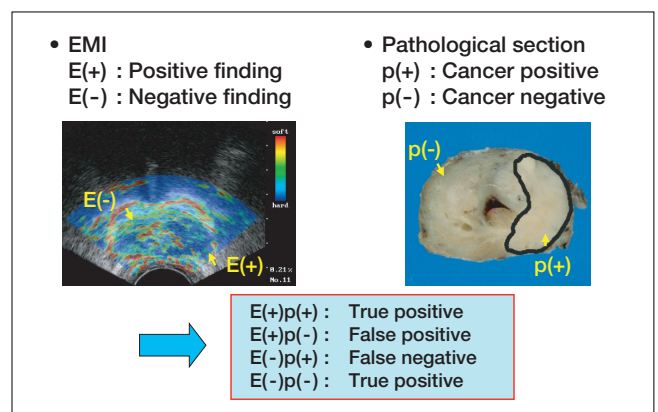


Fig. 5 : Diagnostic classification system for each elastographic moving images (EMI)

2) Each case (Table 1):

Furthermore, we classified every case into 4 different categories. These categories are shown in table 1.

Table 1 : Diagnostic classification system for each case

- Category I : All EMIs completely agree with the tumor location
- Category IIa : EMIs agree with the tumor location, but partially show false-positive images
- Category IIb : EMIs agree with the tumor location, but partially show false-negative images
- Category III : No EMIs agree with the tumor location, or are not able to detect the tumor location

3. Our Elastography system for prostate cancer detection (Fig. 6)

Our Elastography system consists of an external PC, a modified commercial ultrasound scanner (EUB-6500, or EUB-8500) and a transrectal probe. The applied ultrasound probe is a 8~4MHz mutually perpendicular bi-plane probe equipped with dual 10R convex heads (EUP-CC531) which simultaneously enables TRUS biopsy and Elastography. The EMIs were obtained transversely from base to apex of the prostate, respectively. These obtained EMIs were compared with the same pathological transverse sections of the prostate. The duration of elastographic moving images (EMI) per section was about 2 seconds, and these images were recorded in an external PC system.

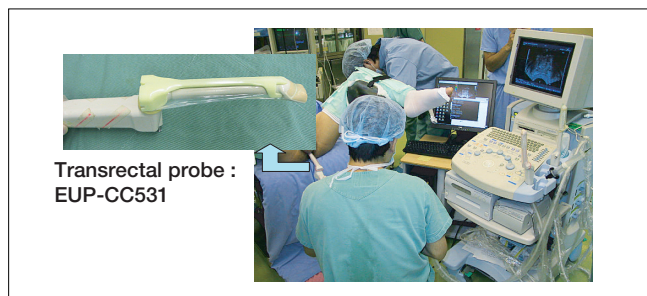

Fig. 6 : TRUS Biopsy under Elastography at Hitachi General Hospital

4. Clinicopathological analysis of Elastography by free-hand compression for prostate cancer detection

We analyzed 51 prostatectomy specimens to examine the feasibility of Elastography by free-hand compression. 516 EMIs were obtained, however, 164 EMIs (32%) were excluded because of 1. poor images due to inadequate compression, 2. moving of the plane during compression. Thus, 352 EMIs, which were 7.5 EMIs per case, were available for analysis (Fig. 7). The profiles of these patients are described in Table 2.

(1) Detection rate of cancer in Elastography alone and Elastography combined with B-mode.

From 352 EMIs, 141 EMIs (43%) were able to correctly detect cancer lesions E(+)_p(+). 71 EMIs were E(+)_p(-),

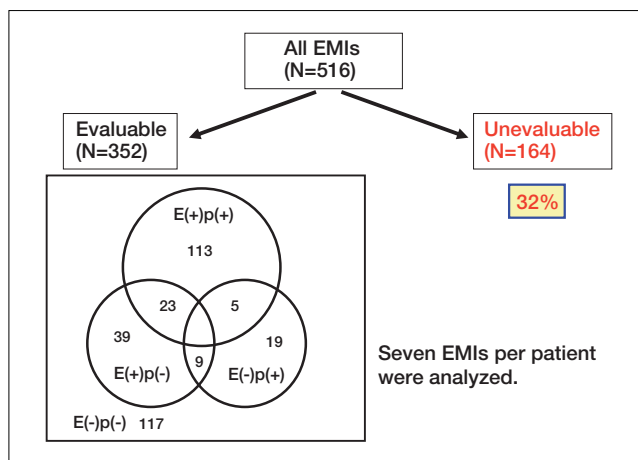


Fig. 7 : Analysis of elastographic moving images of 51 cases

Table 2 : Characteristics of 51 study patients

Age (average) :	52 ~ 74 years (64)
PSA (average) :	3.2 ~ 32ng/ml (11.0)
Clinical stage :	
	Cases
T1c	20
T2a	20
T2b	8
T3a	2
T3b	1

while 32 EMIs were E(-)_p(+). 23 EMIs contained both E(+)_p(+) and E(+)_p(-) lesions, and 5 EMIs contained both E(+)_p(+) and E(-)_p(+) lesions, and 9 EMIs contained both E(+)_p(-) and E(-)_p(+) lesions (Fig. 7).

43 of 51 (84%) cases had cancer lesions detected by Elastography: In 15 cases (29%), all EMIs were in complete agreement with tumor location (category I), 16 cases (31%) belonged to category IIa, and 12 (24%) cases belonged to category IIb. 8 cases (16%) showed disagreement of elastographic findings with tumor location or undetectable tumor by Elastography (category III) (Table 3). In category III, all cases showed low echo on cancer lesions by B-mode.

Table 3 : The Accuracy of Cancer Detection by Elastography

Categories	Cases (%)
I	15 (29%)
IIa	16 (31%)
IIb	12 (24%)
III	8 (16%)

(2) The relationship of tumor location and elastographic findings. (Fig. 8).

We divided prostates into 3 different locations, anterior, middle, and posterior. 26 cases showed single cancer lesions, while 25 cases contained multiple cancer locations, which were individually analyzed. Anterior, middle, and posterior tumors were identified in 32, 17, and 28 cases respectively in step sections. In the 32 anterior tumors, 30 were visualized by Elastography (sensitivity: 94%). Like-

wise, sensitivity was 76% and 57% at the middle and posterior regions, respectively. Anterior cancer lesions were correctly detectable.

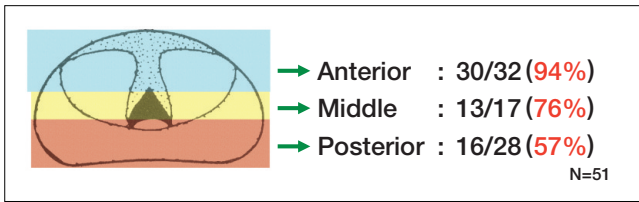


Fig. 8 : The relationship of tumor location and elastographic findings

5. Case presentation of Elastography (Fig. 9)

Anterior case. A 73-years-old man showed elevated levels of PSA of 12.9 ng/ml. No evidence of cancer was detected by DRE, conventional B-mode, and enhanced MRI examination, while Elastography demonstrated a blue-colored signal at the anterior region. Transrectal plus transperineal 12 core biopsy revealed the positive core of prostate cancer. The resected prostate tissue revealed an anterior tumor composed of Gleason 3+4 adenocarcinoma. This was a case in which only Elastography was able to detect the cancer lesion.

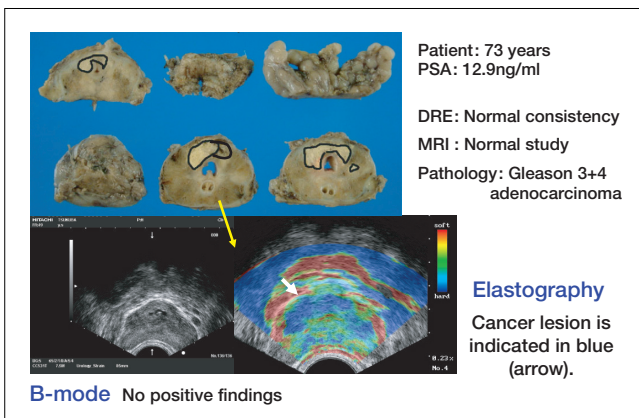


Fig. 9 : Case presentation: Anterior prostate cancer

6. Discussion

Based on clinicopathological analysis, we obtained a characteristic of Elastography, which was an excellent detection rate in the anterior prostate region. In a large PSA-based screening study, 27~40% of prostate cancers detected were not palpable. Anterior prostate tumors are more difficult to find by conventional TRUS, and multiple sets of sextant biopsies or targeting of the anterior prostatic biopsy are necessary for correct diagnosis. Even with MRI, tumor detection was lower in the anterior prostate than in other parts of the prostate due to the greater distance between the coil and the anterior lobe. Elastography is concluded to be currently the most effective tool to diag-

nose anterior prostate cancer. Despite anterior predominance, a poor detection rate was observed for posterior tumors. It is unclear whether this phenomenon is due to the limitation of compressibility depending on the shape of the probe head (i.e. small 10R convex) or our Elastography visualization techniques. Our hypothesis is that those posterior lesions which are directly attached to the probe can be easily displaced, and consequently show false negative results, whereas this is not the case with the anterior lesions. This phenomenon should be resolved in the future, however, and B-mode and DRE could compensate for the posterior low detection of Elastography. BPH nodules were sometimes misdiagnosed as hard masses, which is also a weakness of Elastography. It should be verified whether BPH nodules are genuinely hard or not.

One of the other problems of Elastography was its examiner dependency. To overcome this problem, we first established exclusion criteria and diagnostic classification systems for each EMI and each case. Secondly, we have developed a device to compress the prostate automatically by inflation and deflation of a balloon attached to an endorectal probe. The EMIs obtained by this method were highly reproducible and stable. Now, we are conducting a prospective analysis for prostate cancer screening by Elastography concomitant with B-mode.

In conclusion, Elastography in conjunction with B-mode significantly improved the detection of prostate cancer in this clinicopathological analysis. One of the characteristics of Elastography is its excellent detection of anterior tumors, despite poor detection of posterior tumors, which is compensated for by DRE or conventional B-mode examination.

References

- 1) Krouskop TA, et al. Elastic moduli of breast and prostate tissue under compression. *Ultrasonic Imaging*, 1991; 13: 111-134.
- 2) Konig K, et al. Initial experiences with real-time elastography guided biopsies of the prostate: *J Urol* 174, 2005; 115-7.
- 3) Miyanaga N, et al. Tissue elasticity imaging for diagnosis of prostate cancer: a preliminary report. *Int J Urol* 13, 2006; 1514-1518.
- 4) Tsutsumi M, et al. The impact of real-time tissue elasticity imaging (elastography) for detection of prostate cancer: Clinicopathological analysis. *Int J Clin Oncol*. 12, 2007; 250-255.
- 5) Horninger W, et al. Real-time elastography for detecting prostate cancer: preliminary experience. *BJU Int*. 100, 2007; 42-46.